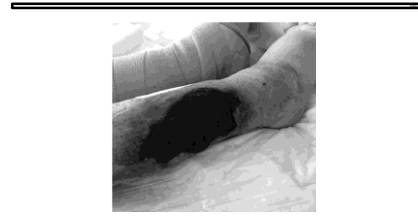
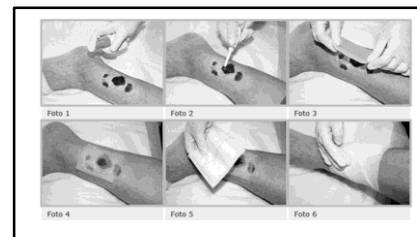
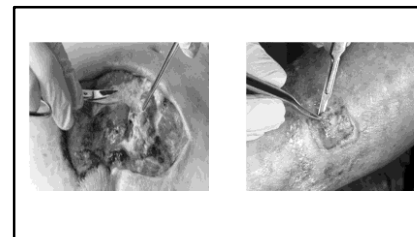
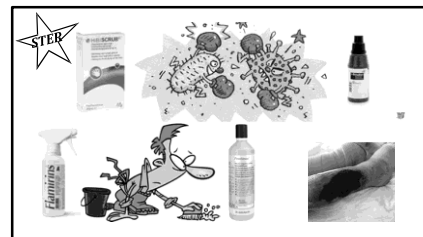
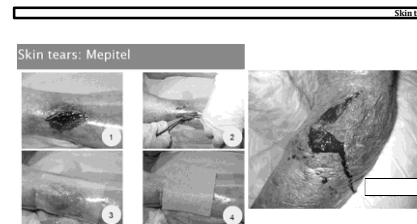
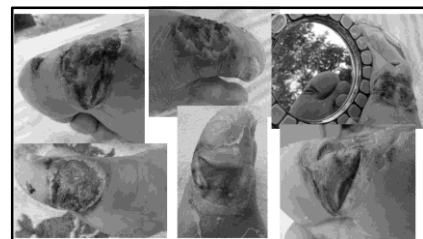
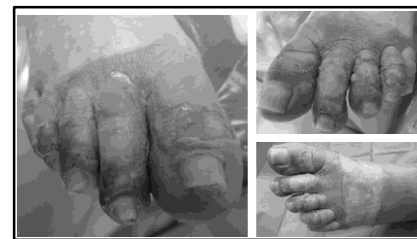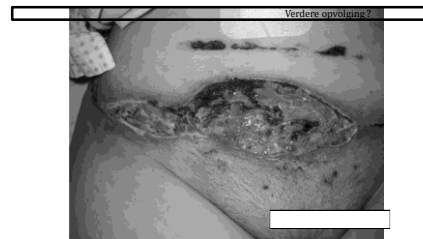


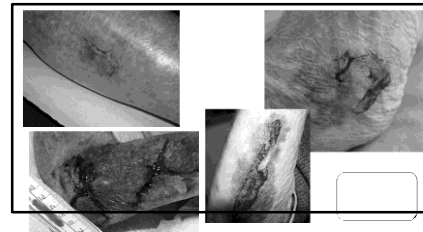


Casus 2: Een bejaarde dame opgenomen op IZ na heupfractuur met val tegen een lade.  
Mevr is gekend met veneuze insuffiëntie  
Bij het verwijderen van de Lastodur® treffen we volgende wonde aan thv van het onderbeen










S DANK VOOR DE AANDACHT



A  
R  
S  
:



The innocence of a child described in one picture.